

PATIENT

Loki Warren

SPECIES

Canine

BREED

Swedish Vallhund

SEX

Intact Male

AGE

7.16.2020

WEIGHT

25 lbs

INTERPRETED BY

Andrea Nicastro,
DVM, Diplomate ACVIM
(Small Animal Internal
Medicine)

IMAGING PERFORMED BY

Andrea Nicastro,
DVM, Diplomate
ACVIM (Small Animal
Internal Medicine)

HOSPITAL NAME

Sun Dog Cat Moon

REFERRING VET

Dr. Abby Clayton

INVOICE

11307

DATE

8.3.2022

PRESENTING CLINICAL SIGNS

Clinical Exam Findings: 1 testicle in scrotum, palpates like L testicle is in L inguinal canal (vs inguinal LN)

ULTRASONOGRAPHIC EXAMINATION OF THE ABDOMEN

Urinary System

The **urinary bladder** wall is normal in thickness and the mucosal surface is smooth. The bladder lumen is moderately distended with anechoic urine. No masses, inflammatory changes or calculi are observed. Ureteral papillae and visualized portion of the proximal urethra, visible to a depth of 2 cm, are normal.

The **prostate** is enlarged (3.00 cm in width) with a normal shape and smooth peripheral contours. The parenchyma is hyperechoic relative to surrounding omental fat and slightly heterogenous in appearance. No distinct focal lesions are observed. The prostatic urethra is not overtly dilated.

The **left kidney** is normal size (5.41 cm in length); normal shape and architecture with smooth peripheral margins. There is a normal 1:3 cortex to medulla ratio with normal corticomedullary distinction. There is no evidence of pyelectasia, nephroliths, infarcts or hydronephrosis. Renal vasculature is normal.

The **right kidney** is normal size (5.92 cm in length); normal shape and architecture with smooth peripheral margins. There is a normal 1:3 cortex to medulla ratio with normal corticomedullary distinction. There is no evidence of pyelectasia, nephroliths, infarcts or hydronephrosis. Renal vasculature is normal.

Adrenal Glands

The **left adrenal gland** is normal size (0.45 cm at cranial pole) (0.42 cm at caudal pole) (2.12 cm in length); normal shape; homogenous parenchyma. The glandular echogenicity and detail are unremarkable. Capsule, cortex, and medullary definition are normal. The phrenicoabdominal vein and surrounding vasculature are normal.

The **right adrenal gland** is normal size (0.96 cm at cranial pole) (0.66 cm at caudal pole); normal shape; homogenous parenchyma. The glandular echogenicity and detail are unremarkable. Capsule, cortex, and medullary definition are normal. The phrenicoabdominal vein and surrounding vasculature are normal.

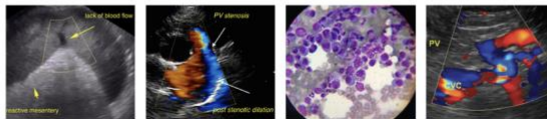
Spleen

The **spleen** is normal in size (1.20 cm in width at the level of the hilus) with a normal capsular contour. There is appropriate echogenicity and echotexture. No focal lesions are observed. Splenic vasculature is normal.

Liver

The **liver** is subjectively normal in size with normal contours and structure. There is appropriate echogenicity and echotexture. No overt structural evidence of inflammatory, infiltrative, or regenerative pathology is evident. Vascular and biliary tracts are of normal volume with no evidence of congestion. No pathological hepatic lymphadenopathy observed. The portal vein to caudal vena cava ratio is approximately 1: 1.

The **gall bladder** lumen is moderately distended. The wall is thin and smooth. Luminal contents are anechoic. The cystic and common bile ducts are normal/not seen.



PATIENT

Loki Warren

SPECIES

Canine

BREED

Swedish Vallhund

SEX

Intact Male

AGE

7.16.2020

WEIGHT

25 lbs

INTERPRETED BY

Andrea Nicastro,
DVM, Diplomate ACVIM
(Small Animal Internal
Medicine)

IMAGING PERFORMED BY

Andrea Nicastro,
DVM, Diplomate
ACVIM (Small Animal
Internal Medicine)

HOSPITAL NAME

Sun Dog Cat Moon

REFERRING VET

Dr. Abby Clayton

INVOICE

11307

DATE

8.3.2022

Gastrointestinal

The **stomach and intestine** are free of stasis and exhibit normal peristaltic activity. The gastric lumen is not distended. The gastric wall and pylorus are normal in thickness with a normal layering pattern. The pyloric outflow tract is patent. The small intestinal lumen is not dilated. The small intestinal wall thickness is normal with a normal layering pattern and appropriate mural detail. Discreet masses are not identified. The colonic wall is normal. There is no evidence of an obstructive pattern.

Pancreas

The region of the **pancreas** is isoechoic relative to surrounding omental fat. No obvious parenchymal abnormalities are observed. There is no evidence of regional inflammation or effusion.

Free Abdomen

The **peritoneal cavity** is normal. There is no evidence of inflammation or effusion. The abdominal **lymph nodes** are normal/not visible.

Other

The **left testicle** measures 2.10 x 0.93 cm and is located intraabdominally ventral-lateral to the urinary bladder.

The **left testicle** is located in the scrotum and measures 2.78 x 1.96 cm.

The testicles are relatively symmetrical with a normal shape and homogenous parenchyma.

A **brief echocardiogram** reveals no evidence of pericardial effusion or obvious right atrial/auricular mass.

ULTRASONOGRAPHIC FINDINGS

Primary Findings

- Left cryptorchid (intraabdominal testicle). The right testicle is descended into the scrotum.
- The prostate changes are consistent with benign prostatic hyperplasia.

INTERPRETATION OF THE FINDINGS & FURTHER RECOMMENDATIONS

Castration is recommended.



PATIENT

Loki Warren

SPECIES

Canine

BREED

Swedish Vallhund

SEX

Intact Male

AGE

7.16.2020

WEIGHT

25 lbs

INTERPRETED BY

Andrea Nicastro,
DVM, Diplomate ACVIM
(Small Animal Internal
Medicine)

IMAGING PERFORMED BY

Andrea Nicastro,
DVM, Diplomate
ACVIM (Small Animal
Internal Medicine)

HOSPITAL NAME

Sun Dog Cat Moon

REFERRING VET

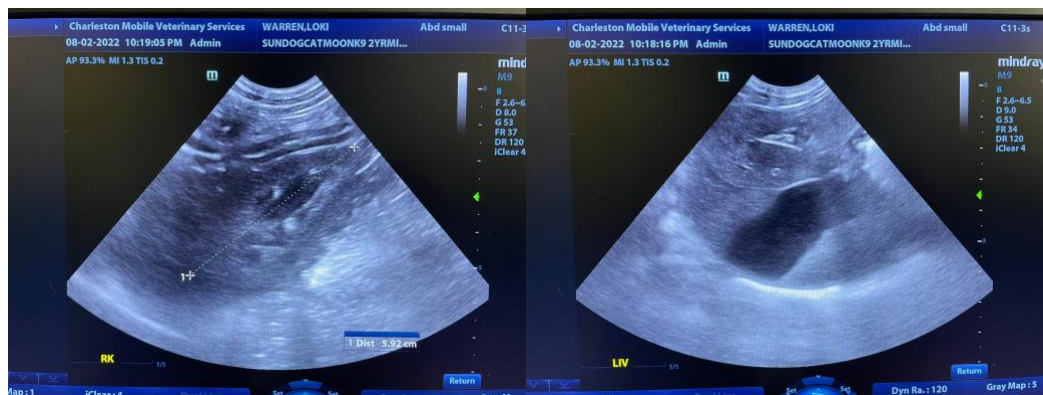
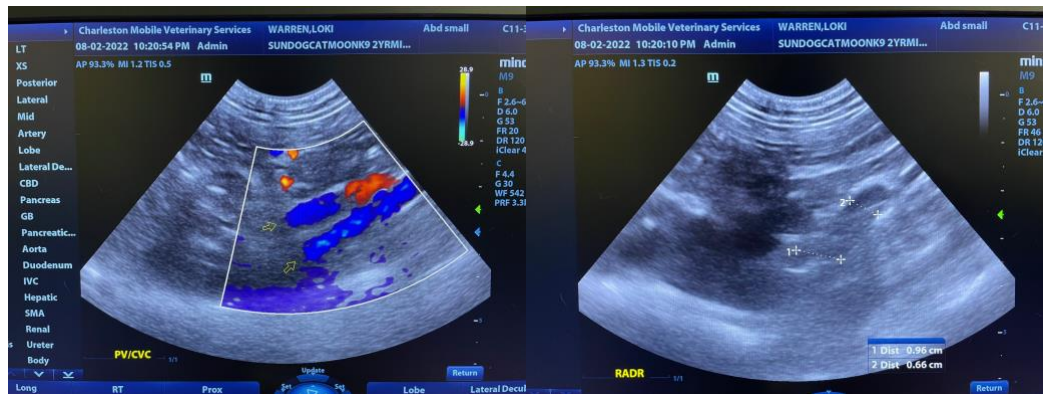
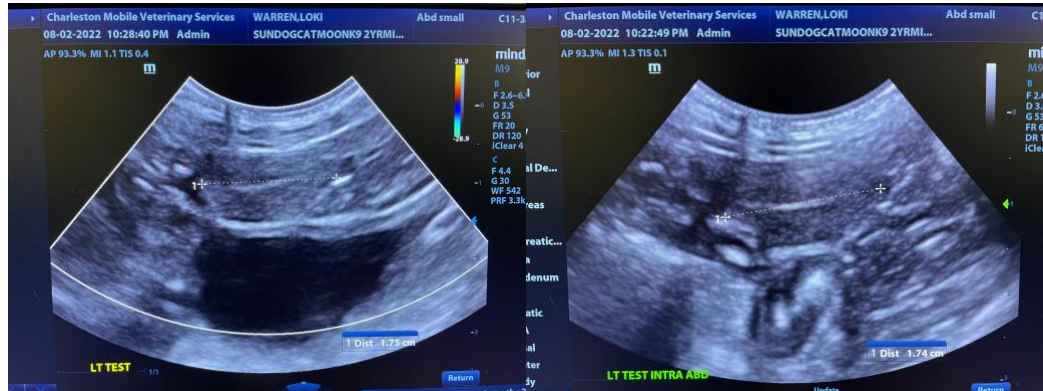
Dr. Abby Clayton

INVOICE

11307

DATE

8.3.2022





PATIENT

Loki Warren

SPECIES

Canine

BREED

Swedish Vallhund

SEX

Intact Male

AGE

7.16.2020

WEIGHT

25 lbs

INTERPRETED BY

Andrea Nicastro,
DVM, Diplomate ACVIM
(Small Animal Internal
Medicine)

IMAGING PERFORMED BY

Andrea Nicastro,
DVM, Diplomate
ACVIM (Small Animal
Internal Medicine)

HOSPITAL NAME

Sun Dog Cat Moon

REFERRING VET

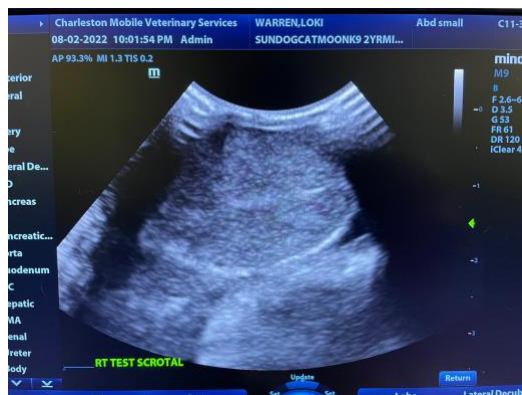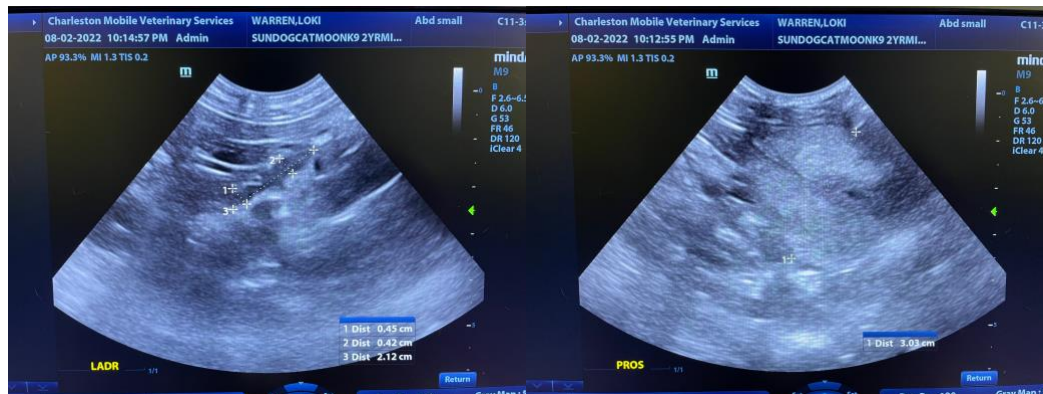
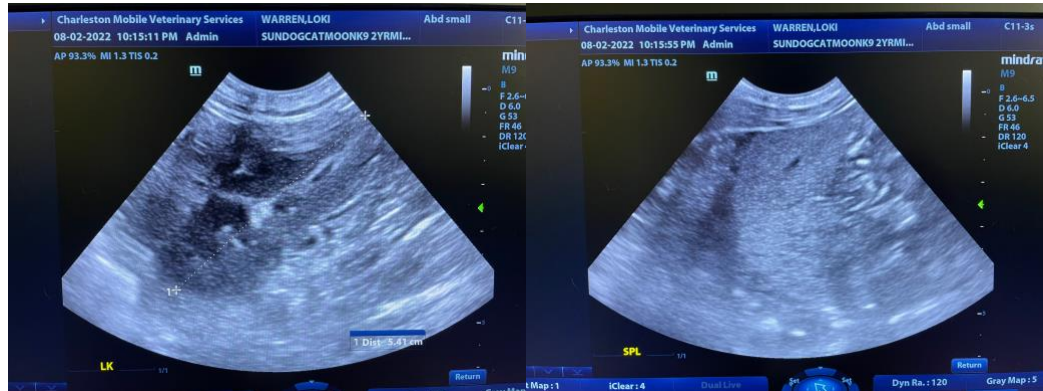
Dr. Abby Clayton

INVOICE

11307

DATE

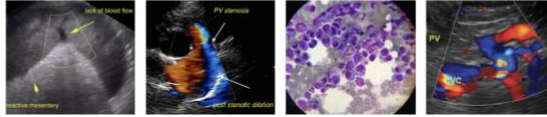
8.3.2022



The information and recommendations provided are based on the images presented by the referring veterinarian/sonographer. No evaluation can be communicated regarding pathology that was not visible in the image/video clips provided.

Thank you for this referral. If the clinical or image interpretation does not parallel your findings or if I can be of any further assistance, please contact me.

Andrea Nicastro, MPH, DVM, Diplomate DACVIM (Small Animal Internal Medicine)
info@SonoPath.com



PATIENT

Loki Warren

SPECIES

Canine

BREED

Swedish Vallhund

SEX

Intact Male

AGE

7.16.2020

WEIGHT

25 lbs

INTERPRETED BY

Andrea Nicastro,
DVM, Diplomate ACVIM
*(Small Animal Internal
Medicine)*

**IMAGING
PERFORMED BY**

Andrea Nicastro,
DVM, Diplomate
ACVIM *(Small Animal
Internal Medicine)*

HOSPITAL NAME

Sun Dog Cat Moon

REFERRING VET

Dr. Abby Clayton

INVOICE

11307

DATE

8.3.2022